

## Comparison of the Efficacy of Digital Caliper and a Newly Designed Digital Bone Gauge for Measurement of Edentulous Alveolar Ridge Width

Reza Amid<sup>\*1,2</sup> Kasra Rahimipour<sup>3</sup> Mahshid Namdari<sup>4</sup> Mahdi Kadkhodazadeh<sup>1,2</sup>

<sup>1</sup>Dept. of Periodontics, School of Dentistry, Shahid Beheshti University of Medical Sciences, Tehran, Iran

<sup>2</sup>Dental Research Center, Research Institute of Dental Sciences, Dental School, Shahid Beheshti University of Medical Sciences, Tehran, Iran

<sup>3</sup>Gifted and Talented Dental Students Division, Students' Research Committee, School of Dentistry, Shahid Beheshti University of Medical Sciences, Tehran, Iran

<sup>4</sup>Dept of Biostatistics, Department of Community Oral Health, School of Dentistry, Shahid Beheshti University of Medical Sciences, Tehran, Iran

### Abstract

**Objectives:** An efficient, safe, affordable and easily accessible measuring instrument for quantitative assessment of bone prior to dental implant placement enables more accurate treatment planning. Costly imaging modalities are neither widely available, nor affordable for some patients. This study sought to assess the efficacy of a newly designed digital bone gauge for measurement of bone width with 0.1 mm accuracy in comparison with a digital caliper.

**Methods:** Using CATIA software, three-dimensional (3D) model of the instrument was designed and its experimental version was fabricated in two models and tested on an edentulous alveolar ridge model. The efficacy of the instrument was assessed by comparing the values obtained by the designed bone gauge with direct measurements made by a digital caliper. The buccolingual width of the edentulous ridge was measured at the crestal level and at 1, 2, 3 and 4 mm apical to the bone crest by the designed bone gauge and digital caliper. The intraclass correlation coefficient (ICC) of the values was calculated.

**Results:** Virtual and experimental models of the instrument were designed and patented. The designed instrument was successfully capable of measuring bone width with 0.1 mm accuracy. The ICC values at 1, 2, 3 and 4 mm apical to the bone crest and at all levels were calculated to be 0.973, 0.994, 0.997, 0.998 and 0.998, respectively.

**Conclusion:** The designed digital bone gauge can efficiently measure bone width at different levels with high accuracy. It can provide valuable and reliable information about bone width at initial clinical examination.

**Key Words:** Bone; Alveolar Process; Clinical Protocols; Dimensional Measurement Accuracy

### How to cite:

Amid R, Rahimipour K, Namdari M, Kadkhodazadeh M. Comparison of the Efficacy of Digital Caliper and a Newly Designed Digital Bone Gauge for Measurement of Edentulous Alveolar Ridge Width. *J Dent Sch* 2017; 35(3):154-162.

\*Corresponding Author:

Amid R

E-mail: Amidperio@gmail.com

Received: 01.05.2017

Accepted: 20.07.2017

## Introduction

By an increase in use of dental implants for masticatory system rehabilitation, influential factors on the success/failure of dental implants have become a topic of growing interest. Implant position is an important factor affecting the success of dental implant treatment, which is dictated by the quality and quantity of bone (1). The quality and quantity

of bone are the two major factors indicating the biomechanical properties of bone; they play a fundamental role in selection of the technique of surgery and type of implant in treatment planning. Adequate knowledge about the properties of the alveolar bone in each patient is necessary for proper treatment planning and deciding on the number of implants required, their diameter and type of loading (2).

Alveolar bone defects are considered a major obstacle against implant placement and necessitate modifying the treatment plan by changing the site of implant placement or conduction of bone augmentation. Detection of these defects prior to surgery would be efficient. The currently available techniques to reveal bone morphology beneath the soft tissue include conventional radiography, 3D computed tomography and bone mapping (direct probing of bone). The 2D conventional radiographs are not efficient for this purpose since they cannot visualize the diameter or buccolingual width of bone, which is necessarily required for selection of implant with a proper diameter. The 3D imaging modalities are highly accurate for measuring bone dimensions. These modalities are currently used along with surgical guides for surgical navigation systems and flapless implant placement. Despite high accuracy and optimal quality, they are not widely accessible due to high cost. On the other hand, not all patients can afford such treatments, and simpler low-cost techniques are highly appreciated by patients and clinicians (3-6).

A consensus has not been reached on a standard technique for assessment of bone quantity in all patients and all clinical settings. Bone mapping appears to be simple and affordable; however, its accuracy highly depends on the operator's experience and skills and it may yield variable results depending on the level of pressure applied, thickness of the overlying soft tissue, hardness of cortical bone and presence of bone defects and concavities in some areas of the alveolar ridge as in the anterior maxilla (7). For the aforementioned reasons, bone mapping is not considered a standard technique to decide on

the proper implant diameter for use. A simple, affordable and easily accessible technique for this purpose can greatly enhance implant treatment planning. Bone gauges were introduced to serve this purpose. However, they have numerous limitations since they measure bone width in two points (buccal and lingual) and one dimension (buccolingually). Buccolingual bone width at the crestal level and a few millimeters apical to the bone crest has high clinical significance. Thus, the current study aimed to design a digital bone gauge with the following criteria: (I) Clinical applicability; (II) measuring and displaying the dimensions digitally with 0.1 mm accuracy to minimize visual errors and (III) using three points at the buccal, lingual and coronal aspects instead of two points to enable 2D measurements (horizontal and vertical). Manufacturing such an instrument would increase the accuracy of dental implant treatment planning and decrease the perioperative and postoperative complications. This study sought to design and compare the efficacy of a digital bone gauge with a digital caliper by direct measurement of bone width on an edentulous alveolar bone model.

## Methods

This study was conducted in three steps: (A) Designing the instrument, (B): fabrication of the instrument and (C) testing its efficacy in comparison with a digital caliper on bone model.

(A) Designing the instrument: This instrument is composed of a mechanical and an electronic part. Both parts were designed with the cooperation of medical engineers in Amir

Kabir University. Its mechanical part includes two horizontal handles, one vertical handle and a screw to adjust the position of vertical handle. It was designed in such a way that when used in the oral cavity, its vertical pin passes through the gingiva and reaches the bone crest at the treatment site; at this position, the clinician closes the handles and the horizontal pins contact the buccal and lingual bone plates at both sides. In this state, the electronic sensors located on the handles measure the distance between the two horizontal pins. By pressing the measurement button on the digital kit, bone width between the two horizontal pins is measured and displayed on the monitor with 0.1 mm accuracy. This value indicates bone width at 1 mm apical to the bone crest and is saved in the memory of the instrument. By adjusting the vertical pin screw, the two horizontal pins are positioned 1 mm apical to their previous position. After reaching the buccal and lingual plates, bone width is displayed and saved. The displayed value at this position indicates bone width at 2 mm apical to the bone crest. The same procedure is repeated to measure buccolingual diameter of bone at 3 mm apical to the bone crest. Using the three saved values, an estimated 2D shape of bone is drawn on the display monitor.

One important point taken into account in designing this instrument is that the sensors and electronic components can be detached from the mechanical component; thus, the mechanical component can be easily autoclave-sterilized.

(B): Fabrication of the experimental model of the instrument: Two experimental models of the instrument were fabricated to assess its efficacy and eliminate possible problems in

order to later fabricate the final model with the ability to sterilize its intraoral components.

(C) Testing efficacy on bone model: A total of 12 points were marked on an edentulous mandibular model. At each point, four levels (1, 2, 3 and 4 mm apical to bone crest) were marked with a waterproof copying pencil. Bone width was measured using the designed bone gauge and a digital caliper with 0.1 mm accuracy. All measurements were repeated twice by the same operator. The Pearson's intraclass correlation coefficient (ICC) was calculated for the data obtained by the designed bone gauge and digital caliper (Figure 1). The instrument was first designed in a computer and then in the Robotic Laboratory of Amir Kabir University. The electronic board of the instrument includes several components as shown in Figure 2, and Figure 3 shows the mechanical part of the instrument.



Figure 1- Edentulous mandibular model used for testing of the efficacy of newly designed bone gauge

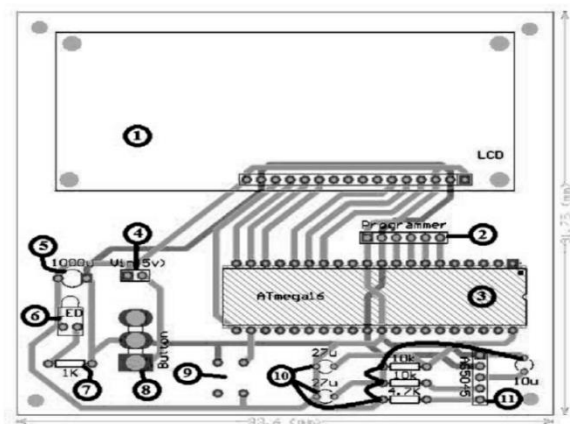


Figure 2- Electronic board of the digital bone gauge. This board includes a ATmega 16

microcontroller with the following components: (I) Display monitor, (II) microcontroller programming port, (III) microcontroller, (IV) 5V power supply, (V) power capacitor, (VI) LED power, indicating that the circuit is on or off, (VII) resistor for LED current control, (VIII) button to turn the circuit on or off, (IX) set button to adjust the zero point and calculate the angle relative to the zero set position, (X) resistor and Biasing IC AS5045 capacitors, (XI) connector connecting the main board to the sensors




Figure 3- Mechanical part of the gauge includes (I) handles adjusting the horizontal pins, (II) location

of magnet and IC magnetic sensor, (III) vertical pin, (IV) horizontal pin, (V) screw to adjust the vertical pin and (VI) wire connecting the magnetic sensor to the main circuit

## Results

To assess the efficacy of the instrument, an edentulous mandibular model and a digital caliper with 0.1 mm accuracy were used. The results of measurements made at 1, 2, 3 and 4 mm apical to the bone crest are presented in Table 1.

Table 1- Bone measurements (mm) obtained with the newly designed bone gauge and caliper at four levels (1, 2, 3 and 4 mm apical to the bone crest) of 12 points marked on the edentulous mandibular bone model

Points	1 mm apical to crest		2 mm apical to crest		3 mm apical to crest		4 mm apical to crest	
	Bone gauge	Caliper	Bone gauge	Caliper	Bone gauge	Caliper	Bone gauge	Caliper
1	5.9	5.8	9.8	9.6	10.4	10.5	13.7	13.7
2	4.9	5	6.5	6.4	10.9	10.7	12.8	13
3	5.1	4.9	6.6	6.6	11.4	11.2	12.2	12.4
4	6.2	6.1	7.8	7.7	8.7	8.7	11.3	11.5
5	6	5.9	6.3	6.4	6.9	7	8.1	8
6	5.3	5.5	6.1	6	6.7	6.8	7.7	7.9
7	5.8	5.9	6.7	6.6	7.9	7.9	8.4	8.5
8	5.4	5.4	6.5	6.7	7.1	6.9	8.4	8.3
9	6.6	6.7	7.9	8.1	9	8.9	11.3	11
10	5.2	5.2	6.8	6.7	10.7	10.9	12.5	12.4
11	5.1	4.9	6.9	7	11	11.1	13	13.1
12	6	6.1	9.5	9.6	10.7	10.6	13.4	13.4

At 1 mm apical to the bone crest, the measurements made by the caliper and the newly designed bone gauge were equal in two points, had 0.1 mm difference in seven points and had 0.2 mm difference in three points. At 2 mm apical to the bone crest, the

measurements were equal at one point, had 0.1 mm difference in eight points and 0.2 mm difference in three points. At 3 mm apical to the bone crest, the measurements were equal at two points, had 0.1 mm difference in six points and had 0.2 mm difference in four

points. At 4 mm apical to the bone crest, the measurements were the same in two points, had 0.1 mm difference in five points, had 0.2 mm difference in four points and had 0.3 mm difference in one point.

The Bland-Altman plots were drawn for different levels (1-4 mm) as shown in Figure

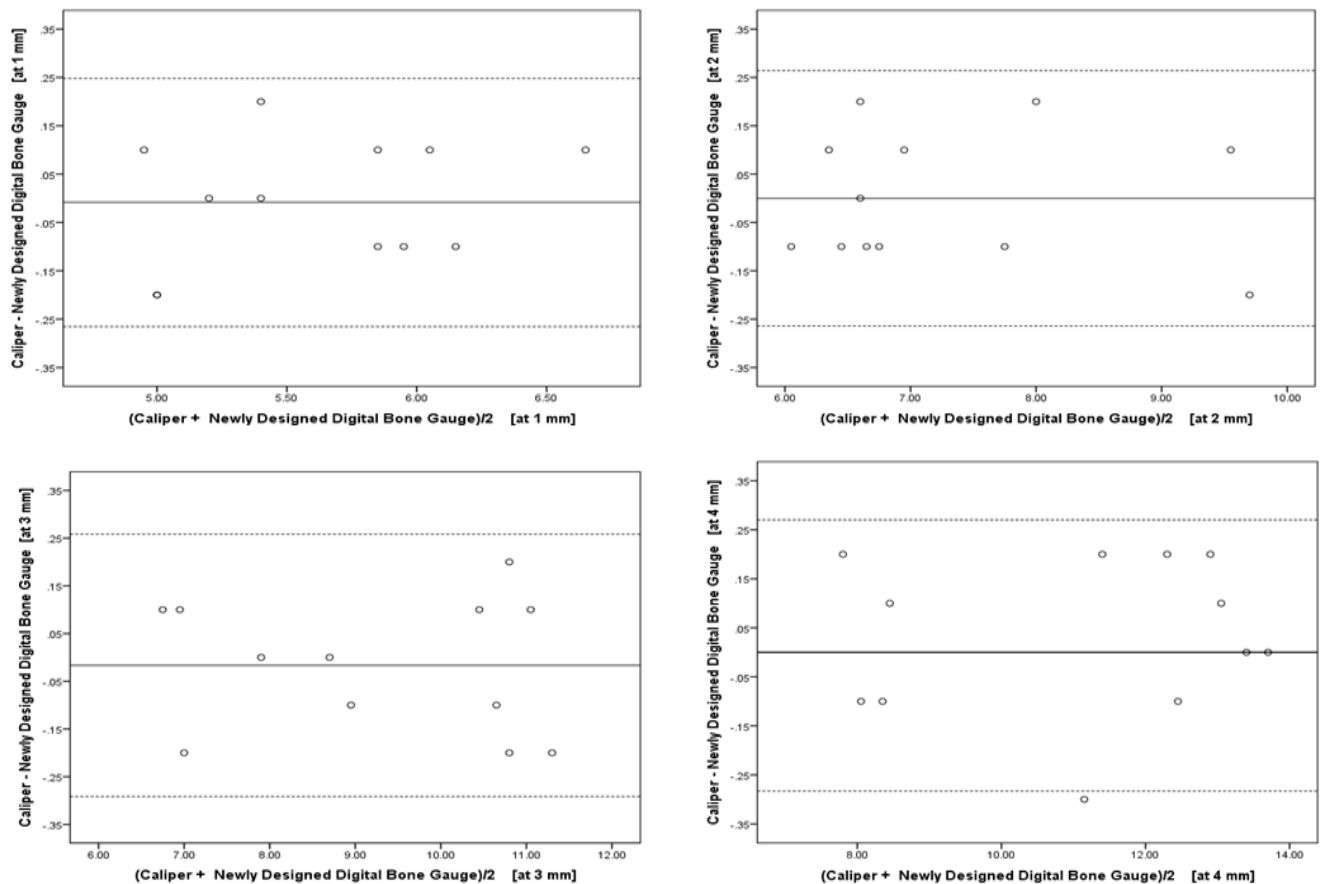


Figure 4- The Bland-Altman plots for different levels (1-4 mm)

The Dahlberg's error of measurement between the two instruments was found to be 0.007917, 0.008333, 0.009167 and 0.0125, at 1, 2, 3 and 4 mm levels apical to the bone crest, respectively. The absolute mean values of difference between measurements made by the two instruments were calculated and compared using one-sample t-test, which revealed that the absolute mean value of differences had a significant difference with zero. The ICC with 95% confidence interval

4. The difference between the measurements made by the designed bone gauge and caliper indicated the error rate of the designed bone gauge; the amount of error at all levels was within the clinically acceptable range of the plot. However, acceptability of such error values is a clinical issue.

was calculated to be 0.973 (0.911,0.992), 0.994 (0.981,0.998), 0.997(0.990,0.999), 0.998 (0.992,0.999) and 0.998 (0.997, 0.999) at 1, 2, 3, and 4 mm apical to the bone crest and at all levels, respectively.

## Discussion

Knowledge about the quantity of available bone prior to dental implant placement is

particularly important. With regard to optimal biomechanics and esthetics of the final prosthetic restoration, implant diameter must be equal or close to the width of the lost bone at 2 mm apical to the cemento-enamel junction (8,9). However, post-extraction bone resorption significantly decreases bone width and causes limitations in selecting implants with optimal diameters.

The 2D and 3D imaging techniques and bone mapping (probing) after administration of local anesthesia have been recommended as the main modalities for paraclinical and clinical assessment of bone quantity, respectively. However, risk of error is high in bone mapping, and 2D radiographs do not allow assessment of buccolingual bone dimensions. On the other hand, 3D imaging modalities such as computed tomography are highly accurate; however, their routine use for all patients increases the treatment costs, and they are not available in many centers (10-13).

In the current experimental study, we showed that our newly designed digital bone gauge was capable of measuring and recording the bone width at different levels from the bone crest up to 4 mm apical to it with high accuracy. Addition of the vertical pin to the bone gauge enabled taking into account the crestal bone position in measurement of bone width. This advantage does not exist in any of the previously designed calipers. Also, digital data output enhances the measurements and accurate recording of data. The current preliminary results confirmed high accuracy of the designed bone gauge since in 53% of the cases, the measurements made by the newly designed digital bone gauge had 0.1 mm difference with the values measured by

the digital caliper; this difference was 0.2 mm in 29% and 0.3 mm in 3% of the cases; similar values were reported by the two instruments in 15% of the cases.

In case of availability of bone width measuring instruments, they can be used to measure the buccal bone thickness particularly in the esthetic zone (13), choose the best treatment plan prior to treatment (14), monitor the dimensional changes of the ridge over time (15) and even for assessment of gingival biotype (16). The above-mentioned parameters are all important for risk assessment and prediction of implant treatment outcome (17). However, bone quality is another important topic, which still necessitates taking 3D radiographs (18,19).

The needlepoint calipers punch the soft tissue and measure the bone thickness; they were popular during the 1970s and 1980s (20). Since the introduction of 3D dental imaging particularly cone beam computed tomography, many clinicians request tomography for all patients with any number of implants and any quality and quantity of bone while in a considerable number of patients, a complete thorough clinical examination would suffice and can provide valuable information; in such cases, there would be no need to order advanced imaging for dental implant placement.

Assessment of bone quantity in only two dimensions and at one level may be one reason for decreased popularity of calipers available in the market. However, the newly designed bone gauge, presented in the current study, enables the measurement of bone width at different levels to provide the clinician with an overall view of buccolingual bone dimensions from the bone crest to 4 mm

apical to it. Such information enables efficient treatment planning for simple cases. In complex cases, 3D radiography may be requested next. We are working on improving this instrument to print a 2D map of bone based on the output data. Obviously, use of this instrument in the clinical setting requires future clinical studies with large sample sizes.

of buccolingual dimensions of bone using an edentulous mandibular model. Such an instrument may decrease the need for costly and less available imaging modalities such as 3D tomography.

**Conflict of interest:** “None Declared”

## Conclusion

The instrument presented in this experimental study had optimal efficacy for measurement

## References:

1. Kniha K, Gahlert M, Hicklin S, Brägger U, Kniha H, Milz S. Evaluation of hard and soft tissue dimensions around zirconium oxide implant supported crowns: a one-year retrospective study. *J Periodontol*. 2016 May;87(5):511-8.
2. Luangchana P, Pornprasertsuk-Damrongsri S, Kiattavorncharoen S, Jirajariyavej B. Accuracy of linear measurements using cone beam computed tomography and panoramic radiography in dental implant treatment planning. *Int J Oral Maxillofac Implants*. 2015 Nov-Dec;30(6):1287-94.
3. Gupta P, Jan SM, Behal R, Mir RA, Shafi M. Accuracy of cone-beam computerized tomography in determining the thickness of palatal masticatory mucosa. *J Indian Soc Periodontol*. 2015 Jul-Aug;19(4):396-400.
4. Shokri A, Khajeh S, Khavid A, Tabari S, Yarmohammadi S. Influence of head orientation in linear measurement for implant planning in cone beam computed tomography. *J Contemp Dent Pract*. 2015 Jul;16(7):542-6.
5. Amarnath GS, Kumar U, Hilal M, Muddugangadhar BC, Anshuraj K, Shruthi CS. Comparison of cone beam computed tomography, orthopantomography with direct ridge mapping for pre-surgical planning to place implants in cadaveric mandibles: an ex-vivo study. *J Int Oral Health*. 2015;7(Suppl 1): 38-42.

6. Zhang W, Skrypczak A, Weltman R. Anterior maxilla alveolar ridge dimension and morphology measurement by cone beam computerized tomography (CBCT) for immediate implant treatment planning. *BMC oral health*. 2015 Jun;15(1):65.
7. Block MS, Scoggin ZD, Yu Q. Assessment of bone width for implants in the posterior mandible. *J Oral Maxillofac Surg*. 2015 Sep;73(9):1715-22.
8. Kopecka D, Simunek A, Streblov J, Slezak R, Capek L. Measurement of the interantral bone in implant dentistry using panoramic radiography and cone beam computed tomography: a human radiographic study. *West Indian Med J*. 2014 Sep;63(5):503-9.
9. Shokri A, Khajeh S. In vitro comparison of the effect of different slice thicknesses on the accuracy of linear measurements on cone beam computed tomography images in implant sites. *J Craniofac Surg*. 2015 Jan;26(1):157-60.
10. Ramaglia L, Sbordone C, Saviano R, Martuscelli R, Sbordone L. Marginal masticatory mucosa dimensional changes in immediate post-extractive implants: a 2 year prospective cohort study. *Clin Oral Implants Res*. 2015 Dec;26(12):1495-502.
11. Chan CK, Chai JY, Wah CT. In vitro ultrasonographic measurement of jawbone to predict bone quality. *Int J Oral Maxillofac Implants*. 2014 Sep-Oct;29(5):1042-8.
12. Kumar A, Mascarenhas R, Husain A. Estimation of soft- and hard-tissue thickness at implant sites. *J Pharm Bioallied Sci*. 2014 Jul;6(Suppl 1):S34-8.
13. Germec-Cakan D, Tozlu M, Ozdemir F. Cortical bone thickness of the adult alveolar process--a retrospective CBCT study. *Aust Orthod J*. 2014 May;30(1):54-60.
14. Guerrero ME, Noriega J, Castro C, Jacobs R. Does cone-beam CT alter treatment plans? Comparison of preoperative implant planning using panoramic versus cone-beam CT images. *Imaging Sci Dent*. 2014 Jun;44(2):121-8.
15. Lee CT, Chiu TS, Chuang SK, Tarnow D, Stoupe J. Alterations of the bone dimension following immediate implant placement into extraction socket: systematic review and meta-analysis. *J Clin Periodontol*. 2014 Sep;41(9):914-26.
16. Malhotra R, Grover V, Bhardwaj A, Mohindra K. Analysis of the gingival biotype based on the measurement of the dentopapillary complex. *J Indian Soc Periodontol*. 2014 Jan;18(1):43-7.



17. Marquezan M, Mattos CT, Sant'Anna EF, de Souza MM, Maia LC. Does cortical thickness influence the primary stability of miniscrews? A systematic review and meta-analysis. *Angle Orthod.* 2014 Nov;84(6):1093-103.
18. Parsa A, Ibrahim N, Hassan B, van der Stelt P, Wismeijer D. Bone quality evaluation at dental implant site using multislice CT, micro-CT, and cone beam CT. *Clin Oral Implants Res.* 2015 Jan;26(1):e1-7.
19. Norton MR, Gamble C. Bone classification: an objective scale of bone density using the computerized tomography scan. *Clin Oral Implants Res.* 2001 Feb;12(1):79-84.
20. Horsman A, Simpson M. The measurement of sequential changes in cortical bone geometry. *Br J Radiol.* 1975 Jun;48(570):471-6.